

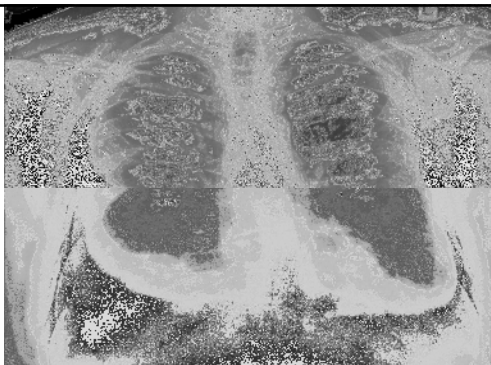
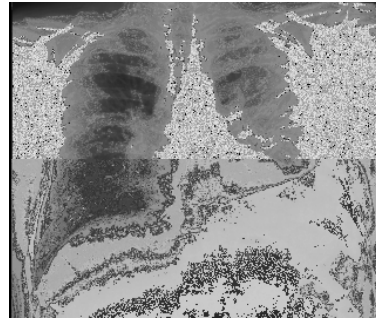
## ARRM 2019

Linda Yen  
North Shore Hospital

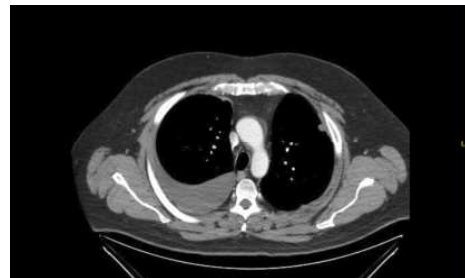## Mr M

- 54yo male
- Worked as a seaman
- Seropositive non erosive rheumatoid arthritis – anti CCP >250
  - Diagnosed in 2005
  - Polyarthritits – large joints (knees, shoulders)
- Treatment – intermittent adherence
  - Triple therapy 2009-2011
  - MTX/LEF combination 2012-2014
  - MTX 2014
  - Variable doses of prednisone

- Dry cough
- Left pleural effusion
- Pleural aspirate: exudative
- Lung function test:
  - FEV1 1.94L (49%)
  - Restrictive pattern secondary to pleural effusion and obesity
- Current smoker 15/day >20 pack years
- BMI 40



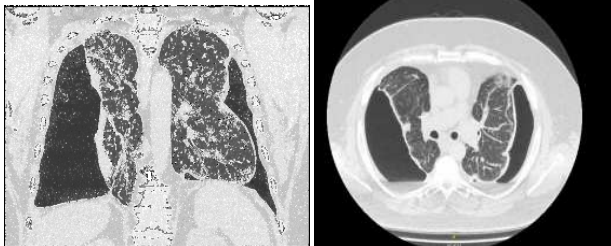
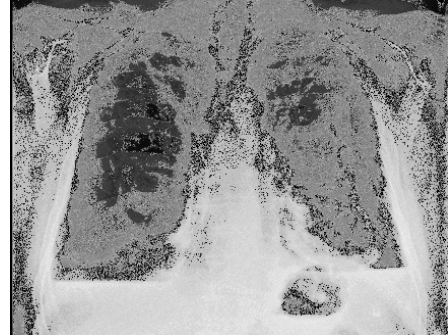
## CT chest 2012 :



2017

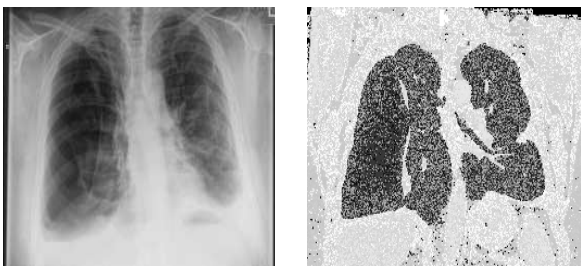
- Increased shortness of breath
- Exercise tolerance 100m
- Chronic productive cough,
- LRTIs with multiple courses of antibiotics

CXR



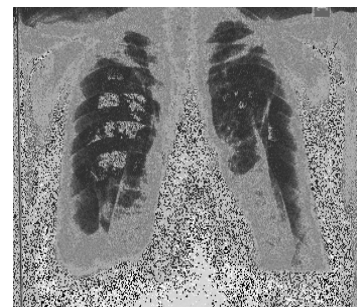
- Methotrexate stopped ? Causing increasing size of pulmonary nodule
- Given IV methylprednisolone – developed rash, with elevated IgE
- Prednisone 40mg daily
  - Gradually weaned down to 7.5mg daily
- Rituximab 1g for two doses 18/1/18 and 01/02/2019
- Hepatitis B core antibody positive – started on lamivudine

CT May 2018



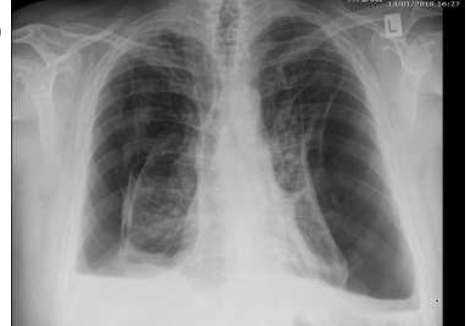October 2018

- Increased SOB
- Chest drain inserted

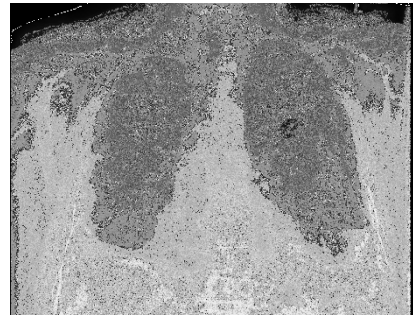


- TALC pleurodesis performed to left lung x2
  - Unsuccessful
  - Recurrence of left pneumothorax
  - Saturation 89-91%
- Further dose of rituximab 1g  
(only one dose given due to further lower respiratory tract infection)
- Discussed in cardiothoracic meeting
  - Surgical option not viable given difficulty of single ventilation either of his lungs in surgery with obesity and poor lung function

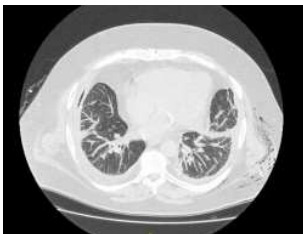Jan 2019



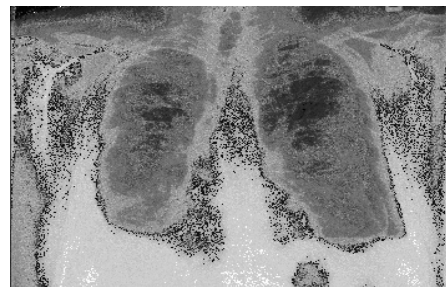
- Elective admission for bilateral chest drain
- Further dose of rituximab given (second dose of the 2<sup>nd</sup> cycle)
- Prednisone 60mg then gradually wean
- 2x doxycycline pleurodesis to the left chest
- 2x TALC to the right
- Pleural biopsy: No malignancy, No TB
  - fibrosis, non specific changes.
  - No plasma cell infiltrate.



CT chest Jan 2019



March 2019



- Total 13 CT chests
- 37 CXR